

# Rupture of the Brachiocephalic Trunk in A 10 Month Old Boston Terrier Bitch at Alberton Veterinary Clinic Johannesburg: A Post-Mortem Case Report

Borden Mushonga<sup>1</sup>, Rungano B. Chipako<sup>2</sup>, Munyaradzi C. Marufu<sup>2,3</sup>, Gervais Habarugira<sup>4,\*</sup>, Phaniel Mponda<sup>2</sup>, Erick Kandiwa<sup>5</sup>, Shepherd Sajeni<sup>1</sup>

<sup>1</sup> School of Veterinary Medicine, Faculty of Agriculture and Natural Resources, University of Namibia, Windhoek, Namibia

<sup>2</sup> Alberton Veterinary Clinic, Alberton, Republic of South Africa

<sup>3</sup> Gauteng Department of Agriculture and Rural Development, Germiston, Republic of South Africa

<sup>4</sup> School of Animal Sciences and Veterinary Medicine, College of Agriculture, Animal Sciences and Veterinary Sciences, University of Rwanda, Nyagatare, Rwanda

<sup>5</sup> Department of Preclinical Veterinary Studies, Faculty of Veterinary Science, University of Zimbabwe, Harare, Zimbabwe

\* Corresponding author: Gervais Habarugira, School of Animal Sciences and Veterinary Medicine, College of Agriculture, Animal Sciences and Veterinary Sciences, University of Rwanda, Nyagatare, Rwanda. Tel: +250-788495249, E-mail: gervais@unrw.ac.rw

DOI: 10.21859/focsci-020440

Submitted: 08.21.2016

Accepted: 10.11.2016

## Keywords:

Haemothorax

Rupture

Spontaneous

Diagnosis

© 2016. Focus on Sciences

## Abstract

**Introduction:** Brachiocephalic artery rupture is a very rare and fatal condition in dogs that is likely to be missed during clinical examination and would normally be diagnosed at post mortem. The aetiology is unknown but is most likely multifactorial and associated with arterial wall degeneration leading to rupture and sudden death due to massive haemorrhage resulting in death from hypovolemic shock.

**Case Presentation:** An intact (unspayed) Boston terrier bitch was admitted into the clinic for sudden onset lethargy. Ante-mortem differential diagnoses which included shocked lung, lung bleeding, diaphragmatic hernia, babesiosis, verminosis and internal bleeding were considered based on history, physical examination, clinical pathology and plain radiography.

**Conclusions:** A definitive diagnosis of fatal brachiocephalic artery rupture was reached at post-mortem examination, performed pro-bono, out of interest with the owner's permission. Ante-mortem diagnosis of brachiocephalic artery rupture is still an unsolved challenge for the practising veterinarian, notwithstanding the recent advances in diagnostics. Fatal brachiocephalic rupture is a rare condition and only has been reported in dogs twice previously.

## INTRODUCTION

Brachiocephalic artery rupture is a very rare condition in dogs and has only been reported twice in literature of recent years [1, 2]. Herein, is described a case of a 10 month old Boston terrier bitch that died of brachiocephalic artery rupture whose cause could not be determined.

## CASE PRESENTATION

A 5.2 kg, 10 month old intact Boston terrier bitch was presented at Alberton Veterinary Clinic in the afternoon with a complaint of a sudden onset of lethargy and not being

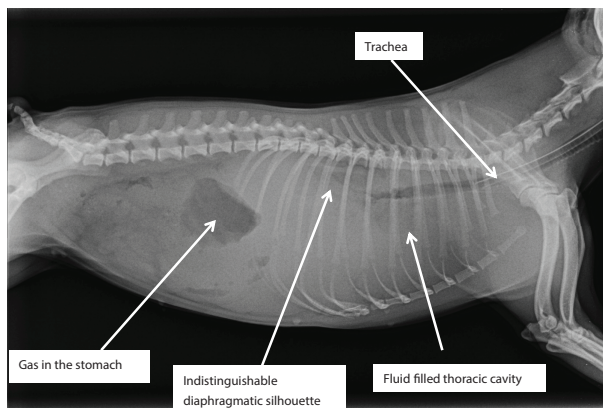
'herself'. The owner reported that the animal was well in the morning and 2 hours prior to presentation; she became dull, inactive and was just recumbent in contrast to her normal investigative behaviour. She had not been vaccinated or dewormed since birth. There was no history of physical trauma. The bitch's diet comprised mainly of commercial veterinary-formulated dog food. The owner had used an unidentified rodenticide to control vermin at the homestead 6 months earlier. The other 2 dogs residing at the same homestead, an adult Labrador and a Jack Russell terrier were both in good health.

Clinical examination of the bitch upon arrival at the clinic

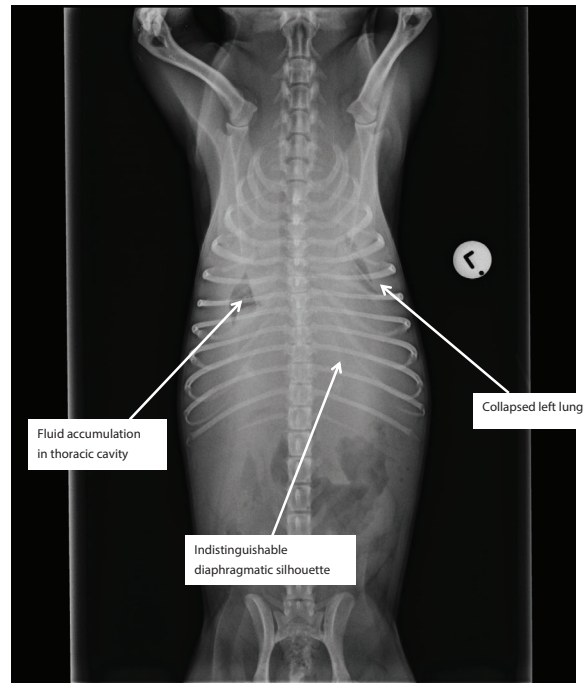
revealed that she was dull and depressed with pale and dry mucous membranes. The capillary refill time was greater than 2 seconds and the rectal temperature was 39.5°C. The heartbeat was increased (168 beats per minute) but regular and the respiratory rate was within reference range (32 beats per minute).

Lateral and ventro-dorsal radiographs (see Figs 1 and 2) of the abdomen and thorax were taken. Abnormalities on radiographs included: no clear diaphragmatic line or silhouette, shocked/collapsed lung (Figs 1 and 2), and gas accumulation in the stomach. Urinalysis was normal and no abnormalities were detected on abdominal palpation. A blood smear detected *Babesia* piroplasm in two of the red blood cells out of 5 fields observed at x100 magnification on a light microscope (Leitz, Germany). The blood picture revealed polychromasia/reticulocytosis. All other parameters were normal and rectal examination ruled out hemochezia.

Based on the history, clinical picture and results of diagnostic tests described above, the following differential diagnoses were considered; shocked lung, lung bleeding, diaphragmatic hernia, babesiosis, verminosis and internal bleeding. The patient was placed on a double bolus of 50 ml Voluven® (Fresenius Kabi South Africa) 30 minutes apart to manage the shocked lungs/lung oedema and dewormed with 100 mg/kg fenbendazole (Panacur®, MSD, South Africa). Treatment for babesiosis was performed by means of slow intravenous injection of 1 mg/kg Trypan Blue (Bayer, South Africa), in conjunction with subcutaneous injection of 2 mg/kg prednisolone (Prednisolone®, Bayer, South Africa) and slow intravenous injection of 4 mg/kg trimethoprim and 20 mg/kg sulphur (Trivetrim®, Fivet Animal Health, Zimbabwe). The bitch showed slight improvement after 12 hours, she started to eat and drink on her own and was stable during overnight monitoring. The following morning, however, the bitch started deteriorating. She was frothing from the mouth with severe dyspnoea and harsh lung sounds. Her heart rate was increased but faint and regular. The patient died within a few minutes of deterioration. A necropsy was requested by the owner to which the clinician agreed and performed with the assistance of a veterinary pathologist.



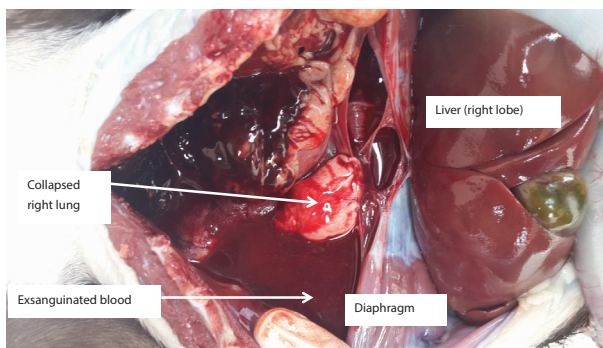
**Figure 1:** Lateral Radiographic View of the Thorax Showing Fluid Accumulation Which Blurred the Thoracic Organs and Showing Absence of Clear Lung Fields



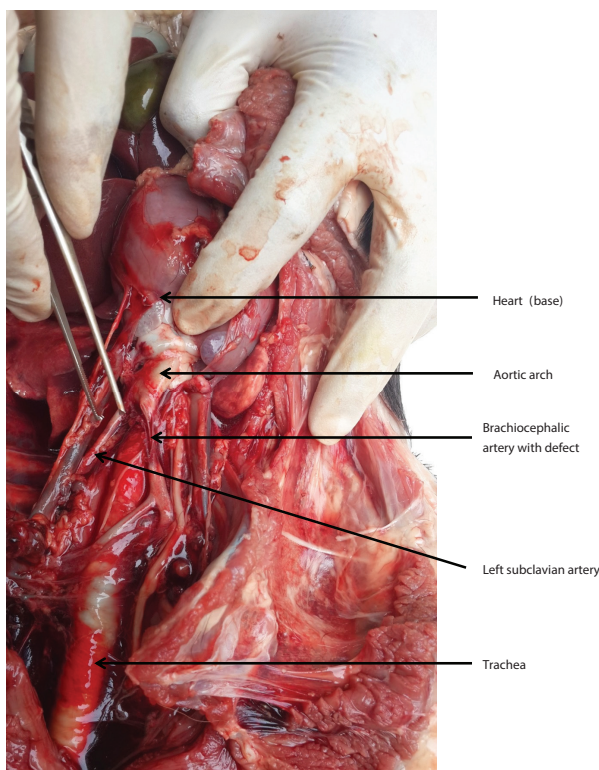
**Figure 2:** Ventro-dorsal Radiographic View of the Thorax Showing Collapsed Lung (More on Left Side than Right Side) Indicating Fluid Accumulation in the Thorax or Inside the Lung Itself

External examination of the cadaver revealed no obvious signs save for pallor of mucous membranes. Upon removal of the skin, blotches of blood were identified surrounding the vena cava on both sides (although more pronounced on the right side). Dissection around the blotches revealed that the blood had a deeper origin deep into the facial planes surrounding both veins. Further inspection of the blotch in the facial planes revealed frank blood that was still fresh filling most of the inter-muscular and inter-vascular facial planes within visceral space of the neck. Opening of the thorax revealed frank blood in the pleural cavities which clotted on exposure to air (see Fig 3). No significant abnormalities were observed in the abdomen, pelvis and the hind or forelimbs. There was nearly 50ml of clotted blood in the pericardium (see Fig 3). Vessel rupture was suspected but the exact vessel that was ruptured could not be easily identified. The pathologist had to wait for about 10 minutes to let most of the blood clot and then follow up initially on all the great vessels including those of the heart and heart wall. Careful blunt dissection of the heart wall, coronary vessels, aortic bulb, ascending aorta and part of the aortic arch yielded no pathological findings. In fact, the density of the blood decreased as the dissection moved further from the heart.

The left subclavian artery did not show any evidence of increased clotting or darkening of clot. Upon following the brachiocephalic trunk, the thickness and the darkening of the clot increased. Careful dissection around the brachiocephalic artery showed a fresh 2 to 3 mm defect that was running along the length of the artery (see Fig 4). The darkened clot could be followed along the *tunica adventitia* of the brachiocephalic artery and into the facial planes separating and surrounding most neck vessels and ventral neck muscles.



**Figure 3:** Post Mortem Picture of the Thorax Demonstrating Exsanguinated Blood in the, Pleural and Pericardial Cavities



**Figure 4:** Further Dissection Around the Brachiocephalic Artery Showing Presence of A Defect

Based on the presence of the defect described above and there being no further pathology in the thorax, it was concluded that the cause of death of the dog was rupture of the right brachiocephalic artery leading to exsanguination and hypovolemic shock.

## DISCUSSION

Brachiocephalic artery rupture as a cause of death in dogs has only been reported twice before [1, 2]. According to Hawthorne and Mandal, the rupture of the brachiocephalic artery was caused by intentional constriction of the subclavian and brachiocephalic arteries in order to investigate how increased blood pressure would affect the brachiocephalic artery [2]. In the second case [1] the immediate cause of death was massive haemorrhage into the mediastinum. In the present case the haemorrhage was into the adventitial space surrounding

the neck vessels, the mediastinum as well as the pleural and pericardial cavities. According to Arimura, Machida [1], histopathological examination of the ruptured blood vessel revealed that the cause of rupture was necrosis of the tunica media and smooth muscle apoptosis resulting in weakening of the vessel walls. Unfortunately, no specimens for histopathology were taken at the time of necropsy in the current case hence an anatomical pathological aetiology of the rupture could not be established.

In the present case, rupture of the brachiocephalic artery occurred along the artery and not at its origin from the aortic arch which is commonly reported to occur in man. The mechanism of rupture following blunt chest trauma is not completely understood but pinching of the artery between the sternum and the vertebral bodies and shear forces associated with hyperextension of the head and neck and the backward migration of the heart at the time of impact of the accident have been suggested [3]. According to Cirillo Jr, McDermott [4], the majority (83 %) of brachiocephalic artery injuries in man occur near the origin of the artery as a result of shear and blood flow turbulence. It is thus possible to infer that trauma might not have played a role in rupture in the current case based on the location of the rupture. Moreover, in the present case, the owner was not aware of any history of trauma involving the bitch. In addition, necropsy did not reveal any bruises or contusions to the chest or any other signs of co-morbid pathology typical of blunt trauma injuries as those described by [4].

Thoracocentesis that was planned for the morning did not take place because the patient died during the morning rounds. Haemothorax and haemo-pericardium were only confirmed at post mortem. It is very possible the brachiocephalic artery was leaking slowly from the previous day and then burst open just before the animal died.

Hawthorne and Manda [2] induced brachiocephalic rupture by simultaneous constriction of the left subclavian and brachiocephalic artery. This caused sudden death due to brachiocephalic rupture in a few of the dogs after a 4-week period. It is also possible that there was some constriction distal to the ruptured part of the artery in this bitch which we might have missed or not thought about during blunt dissection. Unfortunately, we did not measure blood pressure but hypertension would have been detected before the rupture. The presence of frank blood in the pleural cavity as well as fascial planes of the neck muscles in the current case was quite distinct. It was suspected that the brachiocephalic artery could have ruptured as a result of vessel degenerative changes similar to the Arimura, Machida case [1]. It should be noted, however, that unlike the 3 year old dog in Arimura, Machida [1] case, our patient was only 10 months old, an age that does not lend this bitch to be an ideal candidate for degenerative changes associated with the former case.

An equally compelling argument could be that, the degenerative changes in the arterial wall could have been associated with a distal constriction and hypertension as observed by Hawthorne and Mandal [2] and possibly aneurysm observed by Soylu, Harling [5] and Saito, Shiono [6] as a possible cause of rupture of the innominate artery in humans.

There is no literature mentioning the tendency of Boston terriers to develop brachial artery rupture. It is also clear from the history that this dog was fed on a commercial veterinary diet that is low in fats, which was unlikely to cause the de-

velopment of plaques (implicated in degenerative vascular changes) and subsequent brachiocephalic rupture as reported in experimentally fed to genetically engineered Apolipoprotein E knockout mice by Williams, Johnson [7].

The diagnosis of brachiocephalic rupture in the current case was not made during ante mortem diagnostic work-up but only reached after post mortem examination, which is in accord with the report of Arimura, Machida [1]. Diagnosis of arterial rupture in a live animal has been difficult until the last decade as it was difficult to predict when it would occur [8]. In recent years, however, it has become possible to manipulate feeding of genetically engineered Apolipoprotein E to knockout mice and cause the development of arterial plaques which rupture within  $46 \pm 3$  weeks [7]. Even in these cases where plaques have been purposely induced, spontaneous rupture has not been captured at the time of occurrence. In any case a range of 3 weeks is a very long time to be waiting for an arterial rupture to occur at any second of the day. Rupture of the brachiocephalic artery is usually fatal and as a result, diagnosis has only been confirmed at necropsy [1]. Ante mortem diagnosis of the brachiocephalic artery can rarely be accomplished by careful history taking, thorough physical examination, clinical pathology and plain radiographs [9]. Standard radiography would normally reveal enlargement of cranial mediastinum [9, 10] but this can only be picked up by experienced radiologists. Diagnosis can be tricky if there is no history of trauma to the neck. An abnormal plain X-ray warrants further investigation with contrast media and other diagnostic imaging equipment. Diagnostic ultrasound has also been used to pick up aneurysms which occur before the actual rupture [11]. A CT scan can also be handy in the diagnosis of brachiocephalic artery rupture [9]. Some human medical facilities can use FDG PET scans to pick out inflammatory lesions of vessels [12]. Helical computed tomographic aortography and aortography have been used for the diagnosis of acute ruptures of the abdominal aorta in man [4]. For most veterinary practices, such equipment is only for academic interest and would not be found in a developing country suburban practice set up.

There was no chance for treatment of the condition as diagnosis was made during post mortem examination in the present case. Only symptomatic treatment for problems picked out on clinical examination was instituted. Literature reports advocate treatment of this condition before it actually occurs thus, the condition must be suspected after a history of invasive mediastinal procedures or following blunt trauma to the chest or a bullet wound to the chest. This requires a fast and accurate diagnosis. Treatment entails the use vein grafts to seal the rupture [13] or endovascular stent placement [14]. Complications involving the development of aneurysm are not uncommon [11, 14] hence treatment comes with a guarded prognosis.

It was clear that the blood picture was almost normal with no monocytosis, spherocytosis, typical of babesiosis. We believe that the presence of the parasite was of no clinical importance but an incidental finding. However, we found it prudent to institute therapy for babesiosis. Because the bitch had never been vaccinated and spirocercosis is endemic in the Gauteng metropolitan area, we also instituted anthelmintic treatment. This was also in spite of the fact that the *Spirocera lupi* granulomas pathognomonic signs seen on ventral borders of

L2, L3, L4 were not visualised on radiographs of the thorax.

## CONFLICTS OF INTEREST

The authors declare that they have no financial or personal relationships which may have inappropriately influenced them in writing this article.

## ACKNOWLEDGMENTS

The authors wish to thank the owner of the animal for allowing us to publish this case. We are also grateful to the University of Namibia Research and Publications Office (RPO) of the University Research and Publications Committee (URPC) for funding the publication of this manuscript.

## REFERENCES

1. Arimura T, Machida N, Nishida Y, Kiryu K. Fatal rupture of the brachiocephalic artery in a dog. *J Comp Pathol.* 1998;118(2):151-4. [PMID: 9573511](#)
2. Hawthorne EW, Mandal AK. Chronic experimental hypertension in dogs after constriction of brachiocephalic and left subclavian arteries. *Circ Res.* 1962;11:153-60. [PMID: 13905535](#)
3. de Jose Maria B, Gomar C, Mestres C, Sorribes V, Moral V, Sala X. Pseudoaneurysm of the brachiocephalic artery caused by blunt chest trauma. *J Thorac Cardiovasc Surg.* 1995;110(3):863-5. [PMID: 7564461](#)
4. Cirillo Jr RL, McDermott J, Crummy AB. Acute traumatic tear of the base of the brachiocephalic artery after blunt trauma: report of a rare case and review of the literature. *Emergency Radiology.* 2001;8(2):111-6.
5. Soyulu E, Harling L, Ashrafian H, Anagnostakou V, Tassopoulos D, Charitos C, et al. Surgical treatment of innominate artery and aortic aneurysm: a case report and review of the literature. *J Cardiothorac Surg.* 2013;8:141. [DOI: 10.1186/1749-8090-8-141](#) [PMID: 23725538](#)
6. Saito A, Shiono M, Yamamoto T, Inoue T, Hata M, Sezai A, et al. Surgical treatment for innominate artery aneurysm with a coronary pulmonary artery fistula: a case report. *Ann Thorac Cardiovasc Surg.* 2005;11(1):55-8. [PMID: 15788973](#)
7. Williams H, Johnson JL, Carson KG, Jackson CL. Characteristics of intact and ruptured atherosclerotic plaques in brachiocephalic arteries of apolipoprotein E knockout mice. *Arterioscler Thromb Vasc Biol.* 2002;22(5):788-92. [PMID: 12006391](#)
8. Bond AR, Jackson CL. The fat-fed apolipoprotein E knockout mouse brachiocephalic artery in the study of atherosclerotic plaque rupture. *J Biomed Biotechnol.* 2011;2011:379069. [DOI: 10.1155/2011/379069](#) [PMID: 21076539](#)
9. Cohen JA, Bulmer BJ, Patton KM, Sisson DD. Aortic dissection associated with an obstructive aortic chondrosarcoma in a dog. *J Vet Cardiol.* 2010;12(3):203-10. [DOI: 10.1016/j.jvc.2010.05.001](#) [PMID: 21036683](#)
10. Biebl M, Neuhauser B, Perkmann R, Tauscher T, Waldenberger P, Fraedrich G. Traumatic pseudoaneurysm of the brachiocephalic artery following medianoscopy: initial endovascular repair followed by open surgery--a case report. *Am Surg.* 2003;69(6):542-5. [PMID: 12852518](#)
11. Webber GW, Jang J, Gustavson S, Olin JW. Contemporary management of postcatheterization pseudoaneurysms. *Circulation.* 2007;115(20):2666-74. [DOI: 10.1161/CIRCULATIONAHA.106.681973](#) [PMID: 17515479](#)
12. Hayashida T, Sueyoshi E, Sakamoto I, Uetani M, Chiba K. PET features of aortic diseases. *AJR Am J Roentgenol.* 2010;195(1):229-33. [DOI: 10.2214/AJR.09.3952](#) [PMID: 20566821](#)
13. Freeman NE, Leeds FH. Operations on large arteries; application of recent advances. *Calif Med.* 1952;77(4):229-33. [PMID: 13009464](#)
14. Buth J, Laheij RJ. Early complications and endoleaks after endovascular abdominal aortic aneurysm repair: report of a multicenter study. *J Vasc Surg.* 2000;31(1 Pt 1):134-46. [PMID: 10642716](#)